

February 5, 2014 • PARIS

SPECIAL WORKSHOP FOR RADIOLOGISTS, GUIDED BREAST INTERVENTIONS

IMAGING GUIDED BREAST INTERVENTIONS

A WORKSHOP PRESENTED BY THE INTERNATIONAL BREAST ULTRASOUND SCHOOL (IBUS)
THE SOCIETY OF WOMEN IMAGING - SOCIÉTÉ D'IMAGERIE DE LA FEMME (SIFEM)
WITH SENOLOGIC INTERNATIONAL SOCIETY, SIS - INTERNATIONAL SCHOOL OF SENOLOGY AND INSTITUT CURIE, PARIS




Principles of minimal invasive biopsy


C. F. WEISMANN

Diagnostic & interventional Breast Unit
Univ. Inst. of Radiology



General Hospital – Salzburg, Austria






First Principle

Clear unclear findings without diagnostic surgery

- to clear palpable findings with an imaging correlate
- to clear non-palpable findings:
 - Screening MG
 - complementary US
 - complementary MR






First Principle

Clear unclear findings without diagnostic surgery

EUSOMA criteria for diagnosis:

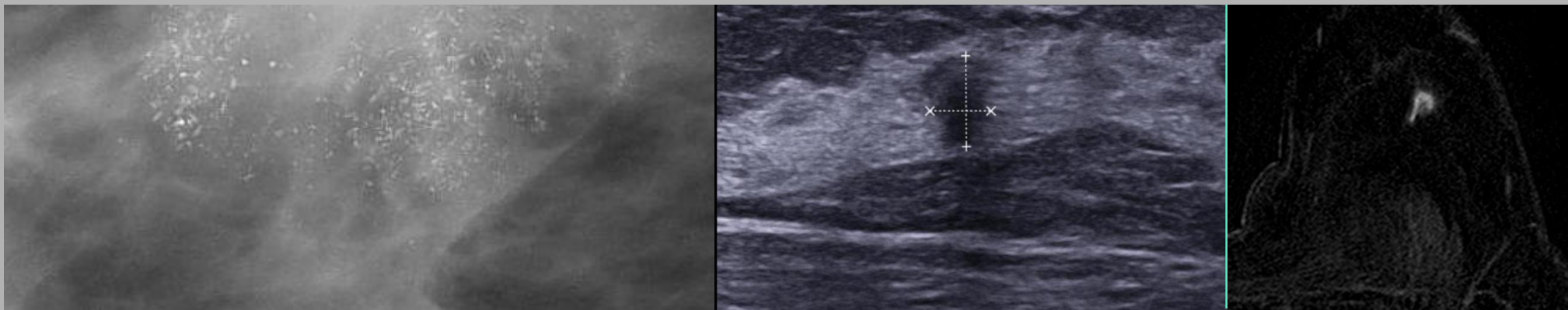
Breast cancer should be preoperatively diagnosed in $>90\%$ by needle biopsy






Second Principle

Choose the imaging technique for guidance,
which offers the best lesion visualisation



If equivocal choose the imaging technique which can offer additional helpful aspects, e.g., real time needle guidance





Third Principle


ALARA

As low as reasonable achievable



How sensitive is the biopsy technique?






From fine-needle to vacuum aspiration biopsy

FNAB (=FNB): Cytology

Needles from 20 G to 23 G
(0.9-0.6 mm outer needle diameter)

FNAB: Sensitivity 53% - 99%






From fine-needle to vacuum aspiration biopsy

FNAB (=FNB): Cytology

FNB depends on quality of cellular material

FNAB: Sensitivity 53% - 99%






From fine-needle to vacuum aspiration biopsy

FNAB (=FNB): Cytology

Disatvantage: no differentiation between invasive or in situ

* nach B. Bode, B.Padberg, *Abt. f. Zytologie, Inst. f. Klinische Pathologie, Univ.-Spital Zürich, Manuskript im Rahmen des 1.Seminars f. fortgeschrittene Mammadiagnostik, Zürich, 2004, S 33*







From fine-needle to vacuum aspiration biopsy

FNAB (=FNB): Cytology

Indications for FNAB:

- for differentiation of cystic vs. solid
- for cyst fluid aspiration
- Lymph node sampling






From fine-needle to vacuum aspiration biopsy

Core needle biopsy : histology

needles $\geq 18G$ – typically 14G (large core needle)
1mm (18G) - 2 mm (14G) outer needle diameter

Large core needle biopsy: sensitivity 92% - 99%






Fourth Principle

More tissue is better than less tissue,
little tissue is better than cells

German consensus-paper:

- >70% of non-palpable cancers should be preoperatively diagnosed by histology under stereotactical or ultrasound guidance (core needle oder vacuum-biopsy)
- false-negative-rate <5%
- false-positive-rate <1%






From fine-needle to vacuum aspiration biopsy

Core needle biopsy : histology

Indications for core needle biopsy (typically 14G):

- BI-RADS IV + BI-RADS V lesions





From fine-needle to vacuum aspiration biopsy

Core needle biopsy : histology

- Overall miss rate in Lit.: 2% - 4%
- False-negative-rate: 1.2% * (in Lit.: 0.3% - 8.2%; mean value in Lit. 4.4%)



* *RJ. Jackman et al. Stereotactic, automated, large-core needle biopsy of nonpalpable breast lesions: false-negative and histologic underestimation rates after long-term follow-up. Rdiology 1999; 210: 799-805*





From fine-needle to vacuum aspiration biopsy

Core needle biopsy : histology

- Underestimation:

ADH: in 58% * CA in final histology after surgery (in Lit.31% - 88%)

Radiary scar: in 40%* CA in final histology after surgery

DCIS: in 15%* invasive Ca in final histology after surgery (in Lit.15% - 36%)



ADH and radiäry scar are „high risk lesions“ for core needle biopsy!
Consequence: surgery!????

* *RJ. Jackman et al. Stereotactic, automated, large-core needle biopsy of nonpalpable breast lesions: false-negative and histologic underestimation rates after long-term follow-up. Rdiology 1999; 210: 799-805*

Management of risk lesions
 IBUS Consensus 25.1.2014
Data collected by C. Rageth



IBUS SEMINAR 2014
INTERNATIONAL BREAST
ULTRASOUND SCHOOL

JANUARY 24, 25, 2014
 TECHNOPARK Zürich




	Diagnosis made by CNB	Diagnosis made by VAB
FEA	wait and see (VAB or OE of visible lesion)	wait and see is justified if the radiological lesion has been removed
Radial scar	VAB or OE of visible lesion	wait and see is justified if the radiological lesion has been removed
Papillary lesion without atypia	Remove larger or symptomatic (and especially peripheral) Papillomas.	
Papillary lesion with atypia	OE	OE
Phylloid tumor	OE. Free margins in borderline and malignant PT's	Follow up in completely excised benign PT's seems to be justified*
LN classical type	OE or VAB (remove US-visible lesion). High risk follow-up if lesion is removed	OE. High risk follow-up if lesion is removed
ADH	OE	OE. If lesion is removed completely and only focal ADH with calcifications, wait and see could be justified.
DCIS and pleomorphic LN	OE	OE

CNB: core needle biopsy. VAB: vacuum assisted biopsy. OE: open excision. FEA: flat epithelial atypia. LN: lobular neoplasia. PT: phyllodes tumor. ADH: atypical ductal hyperplasia.

It is important, that imaging and pathological results are concordant, and that tissue sampling is sufficient

*Park HL (J Breast Cancer 2012) excised 53 benign phyllodes tumors with US-guided VAB with just 1 recurrence in the follow up




From fine-needle to vacuum aspiration biopsy

Mammotome biopsy : histology

Needles: 8G – 14G, typically 11G
(~ 3-4 mm outer Diameter)

In literature: sensitivity - 100%





From fine-needle to vacuum aspiration biopsy

14G core needle biopsy: ~ 18 mg tissue / specimen

11G-VAB:

minimum 15 specimens / lesion

minimum 20 specimens / microcalcifications






Vacuum asp. biopsy



Vacuum can

Vacuum pump



lateral vacuum





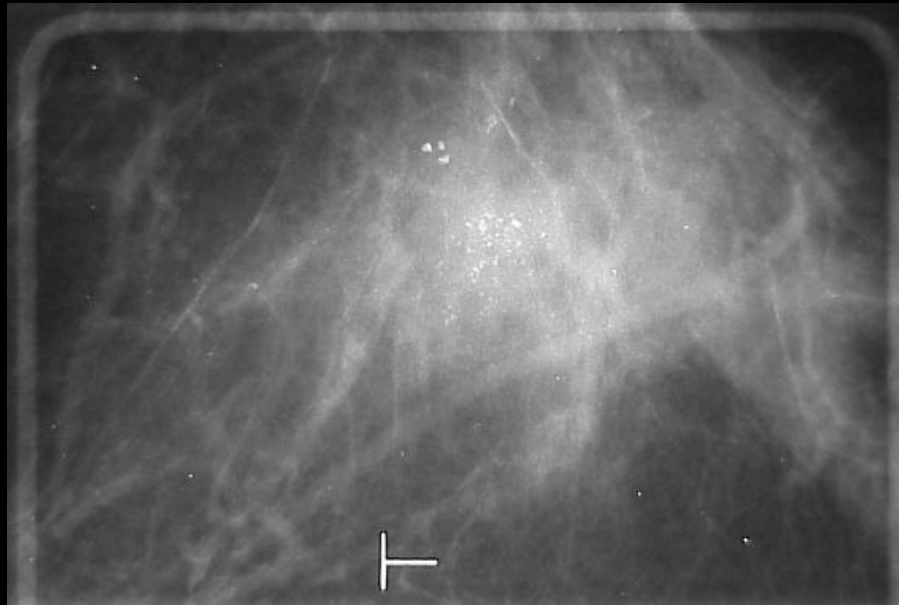

Vacuum asp. biopsy



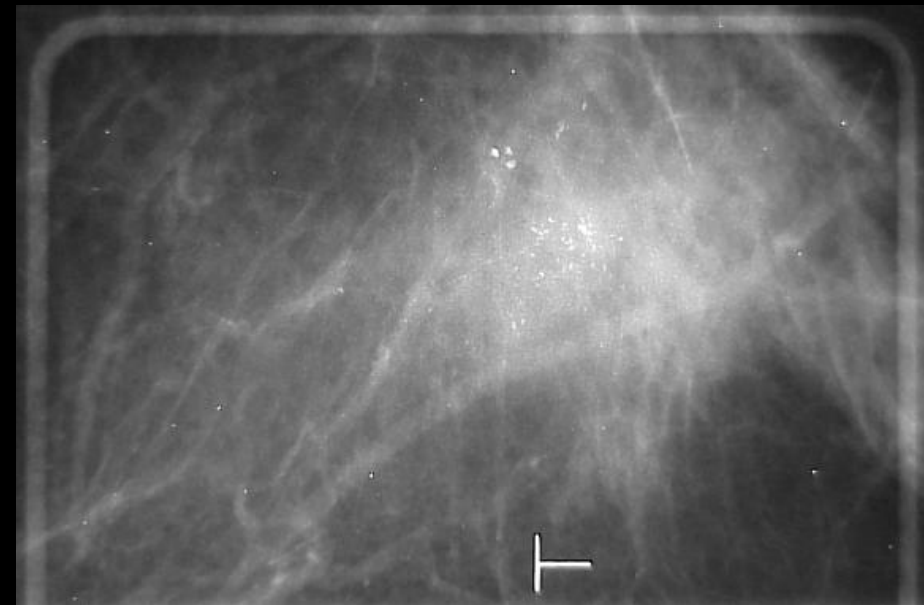
Sampling chamber



Stereotactical guided biopsy of microcalcifications




+ 15 degree stereo views

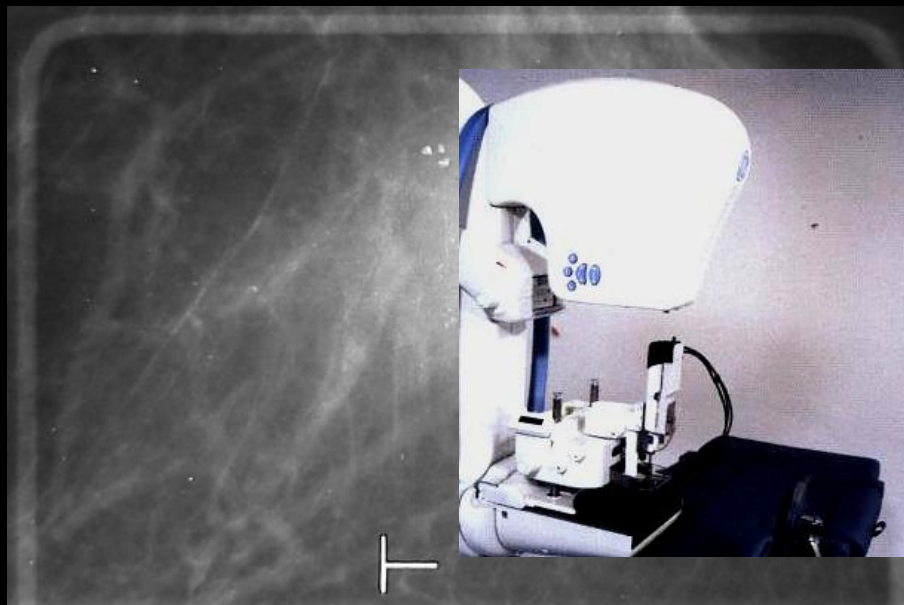


- 15 degree stereo views

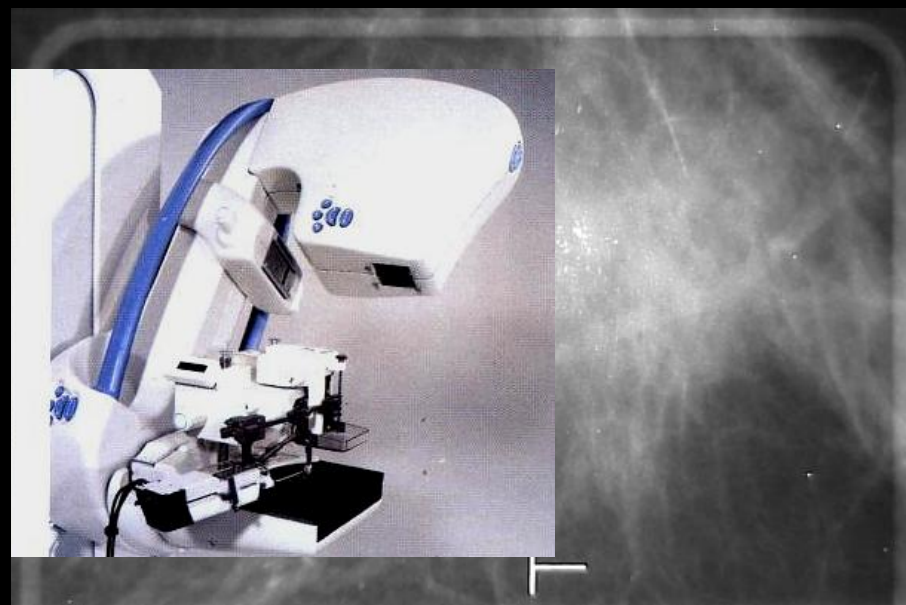




Stereotactical guided biopsy of microcalcifications



+ 15 degree stereo views




- 15 degree stereo views

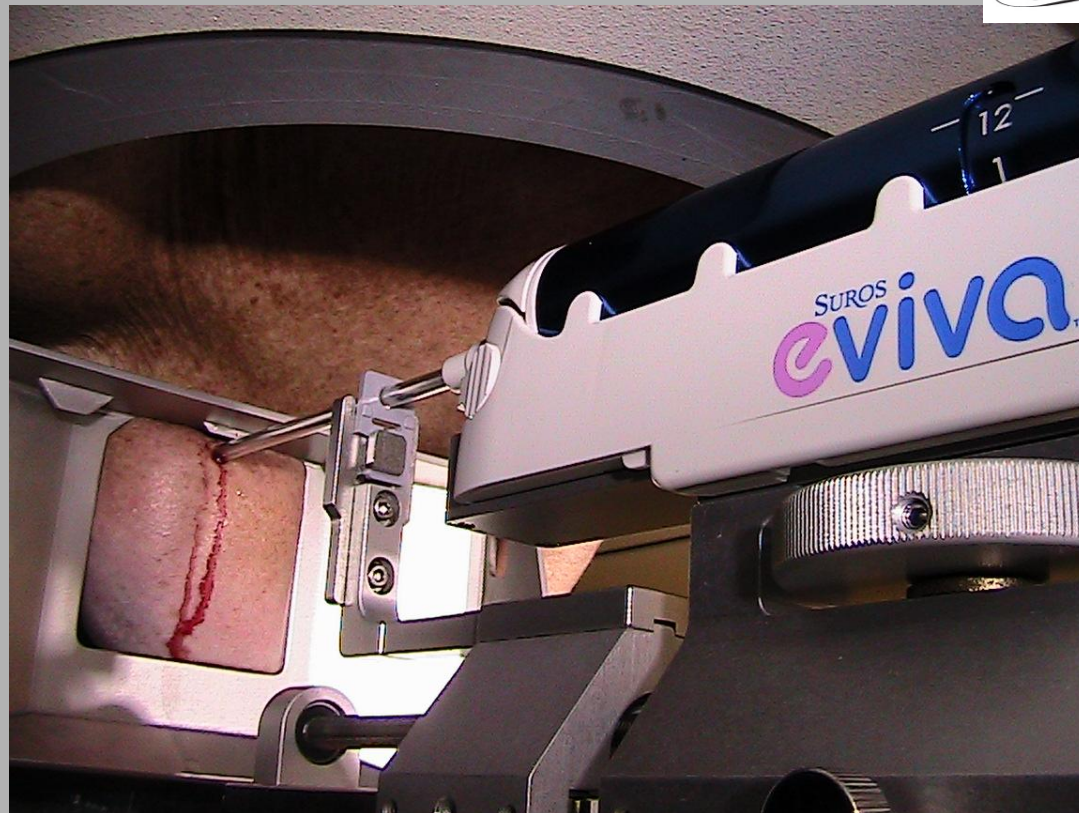




Vacuum assisted breast biopsy




9 G needle



Vacuum assisted breast biopsy




Decision: LCNB vs. VB for diagnostic indications



Can LCNB offer a true pos. result with high probability?

- How clear is the target?
- How representative is the tissue obtained by LCNB?
- What is the BI-RADS classification?
- What is the most probable diagnosis?






Fifth Principle

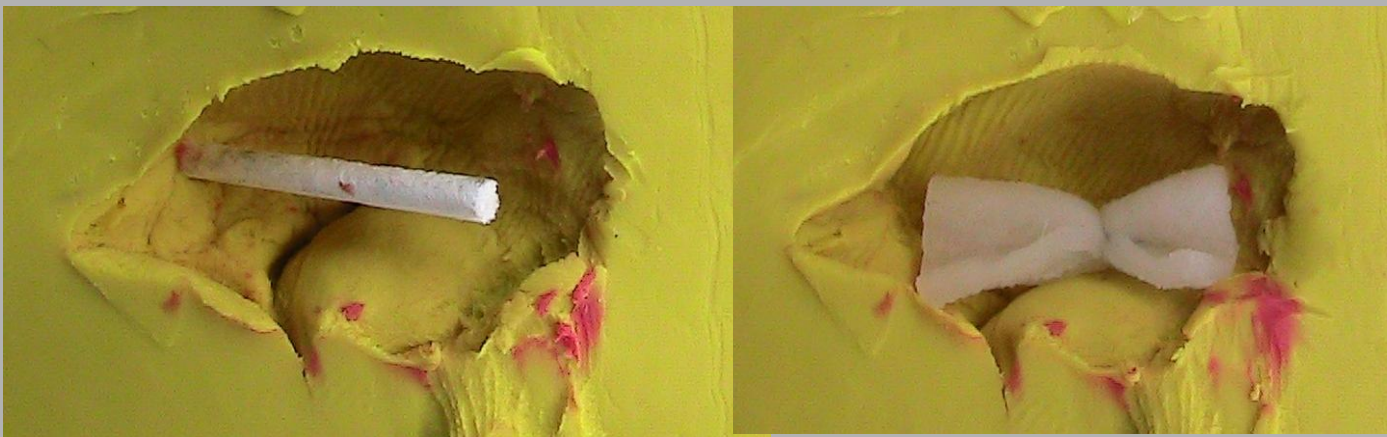

Don't mask the target!

You have to find the lesion or biopsy site after biopsy safely!





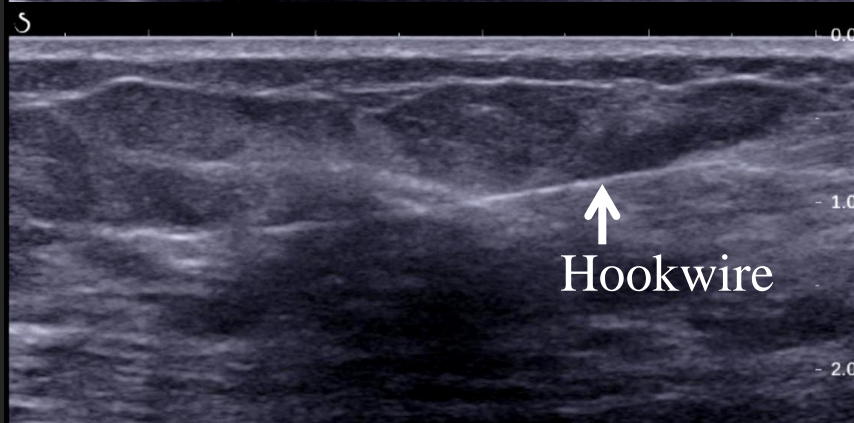
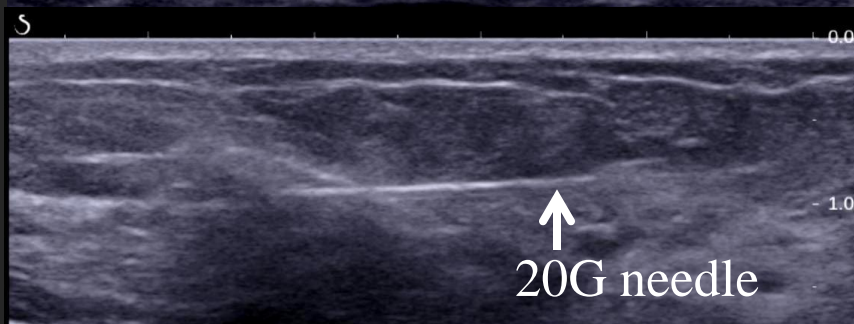
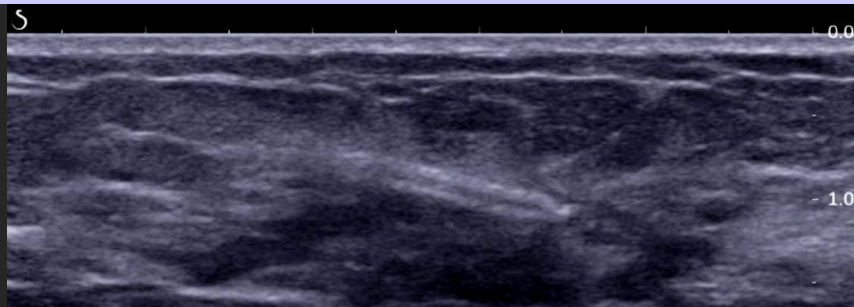
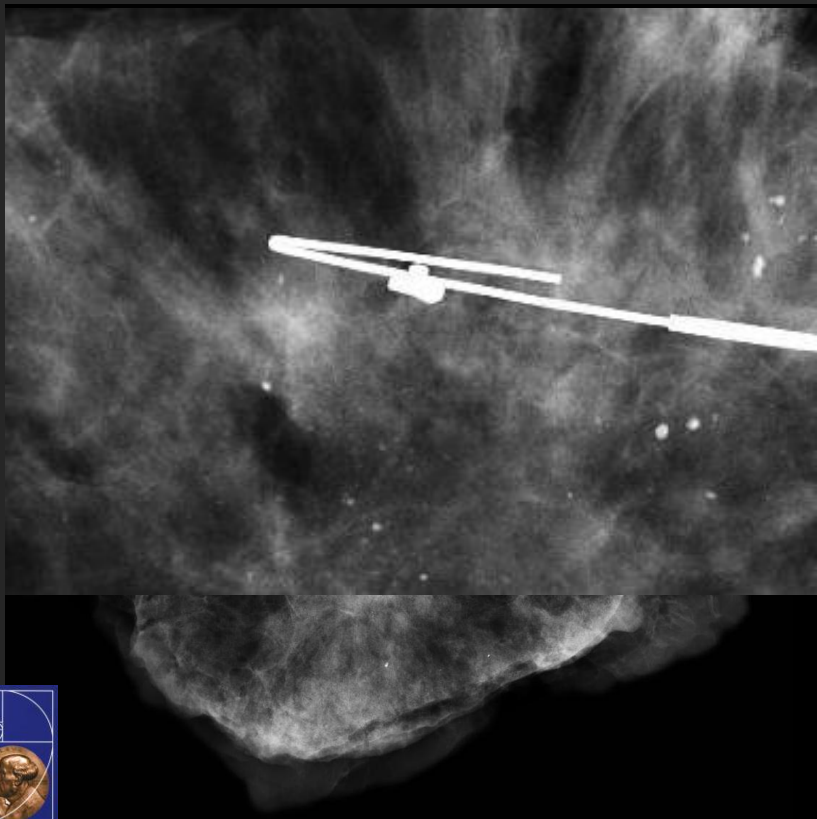

From fine-needle to vacuum aspiration biopsy




Bio-absorbable netting

Recommendation: marker placement in lesions and microcalcified biopsy areas

Hook wire placement






Sixth Principle

Check the concordancy!

Histology has to be concordant with imaging






Sixth Principle

Check the concordancy!

- BI-RADS 4A benignancy expected (prob. of mal. 3-10%)
- BI-RADS 4B benignancy more probable than mal. (prob. of mal. 11-50%)
- BI-RADS 4C malignancy more probable than ben. (prob. of mal. 51-94%)
- BI-RADS 5 malignancy expected (prob. of mal. > 95%)





Sixth Principle

Check the concordancy!

BI-RADS 4C


benign histology

rediscuss your images

if concordant
follow-up after 6 month

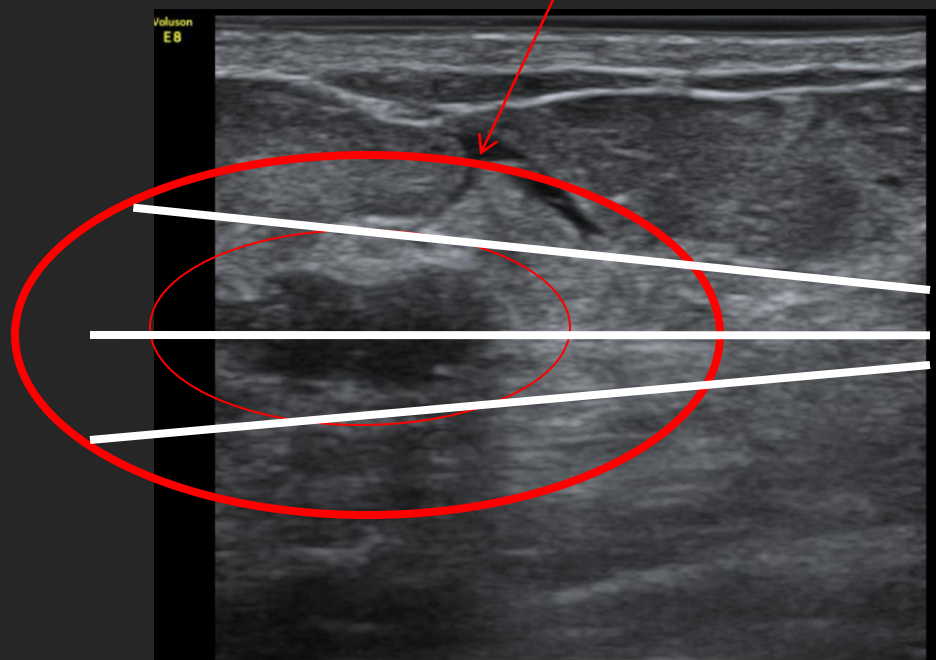
if discordant
REBIOPSY





Tip: use enough local anesthesia !


15-20 ml (without vasoconstrictor)



Lesion „embedded“
by local anesthesia

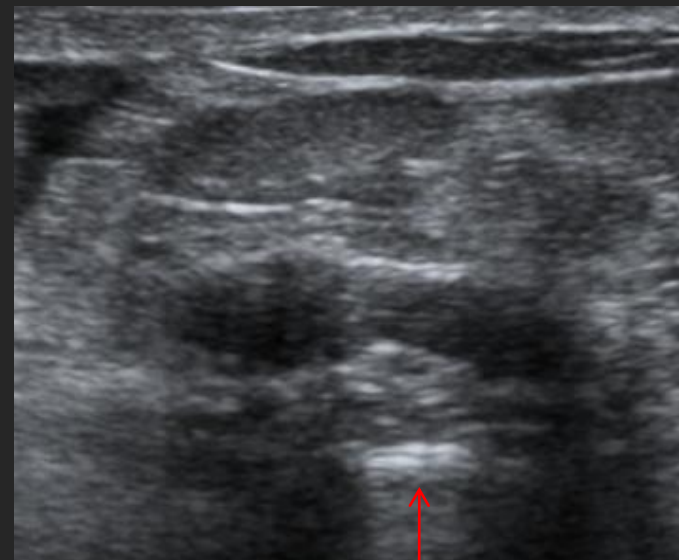
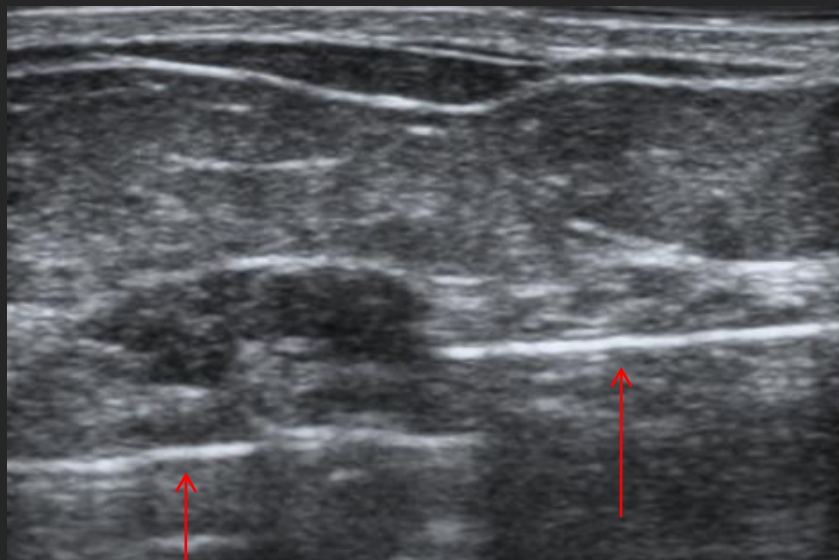
Fibroadenoma before exstirpation






Technique of US-guided biopsy for VAB lesion resection

- 1) the needle is below the lesion
- 2) the needle is in the mid-lesion position



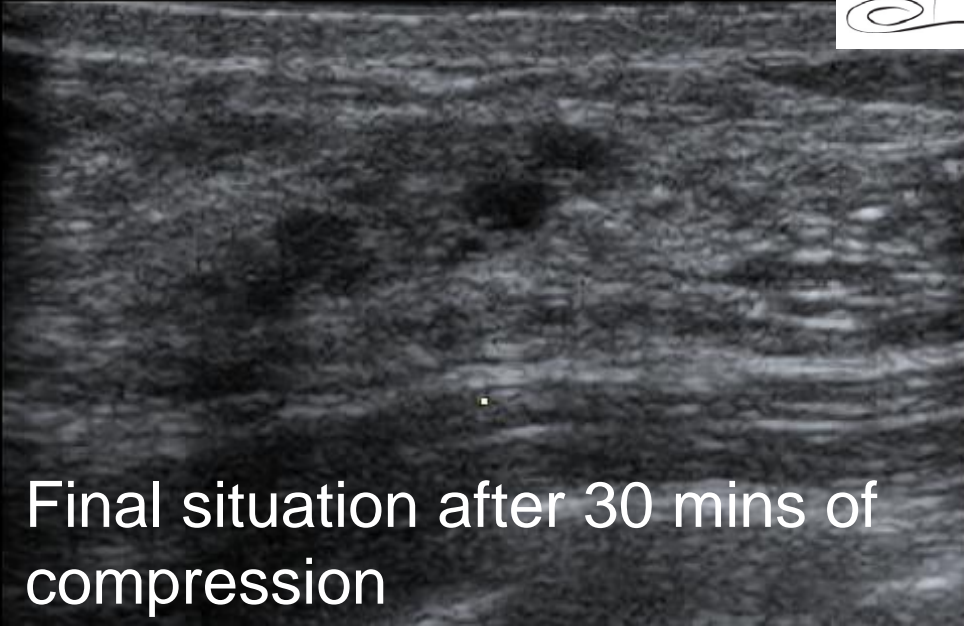


Technique of US-guided biopsy

GE



Start




Final situation after 30 mins of
compression

Fibrozytic mastopathic lesion



Conclusions & Take home message



Clear unclear imaging findings by needle biopsy

Use the optimal guidance technique

Choose the optimal needle discussing needle sensitivity

Use markers to detect a lesion safely after biopsy

Discuss discordant histological vs. imaging results



